

E. Ambu, M. Fimiani, M. Vigna*, S. Grandini

Department of Odontostomatologic Sciences
University of Siena, Italy

*Private Practice, Rimini Italy

email:margheritafimiani@hotmail.it

Use of bioactive materials and limited FOV CBCT in the treatment of a replanted permanent tooth affected by inflammatory external root resorption: a case report

ABSTRACT

Background Inflammatory external root resorption is one of the possible complications of replantation of an avulsed tooth. Several studies have shown that limited FOV CBCT is an efficient diagnostic support and in treatment planning of these cases in paediatric patients because of its high resolution combined with low radiation doses. The recent literature has suggested that Biodentine is an effective material for resolution of inflammatory root resorption.

Case report This article describes the successful therapy of a replanted tooth affected by inflammatory root resorption. In the present case, a CBCT exam was performed to detect the extent of the damage, and the canal was filled with Biodentine in the apical third. At present, the threatened tooth is asymptomatic, and the twelve months follow-up examination showed healing of periradicular hard tissues.

Keywords Bioceramics; CBCT; External resorption; Paediatric dentistry.

Introduction

Dental avulsion entails the complete displacement of a tooth from its alveolar socket [Casaroto et al., 2010], which can affect the pulp and periodontal ligament (PDL), dental hard tissues, alveolar bone, and gingiva. The reported incidence of dental avulsion ranges from 1 to 16% of all traumatic injuries to permanent dentition.

For this type of injury the recommended treatment is immediate replantation [Diangelis et al., 2012] of the tooth, followed by the use of splints, endodontic treatment, and both clinical and radiographic monitoring. One of the most serious complications in replanted permanent teeth is inflammatory external root resorption (IERR), a progressive condition that may irreversibly damage the root structure leading to tooth loss. IERR is triggered by pulp necrosis and infection of the root canal after a traumatic injury to the PDL and root surface [Bastos et al., 2015].

Clinical guidelines [Hinkfuss and Messer, 2009] for the management of avulsed teeth recommend pulp extirpation (PE), and it has been demonstrated that the likelihood of successful periodontal healing is improved by PE within 14 days of replantation because of decreased risk of developing inflammatory resorption; otherwise PE delayed beyond 14 days increases the risk of IERR. When resorption is already initiated, elimination of bacteria from the root canal and its three-dimensional sealing with endodontic therapy is mandatory to arrest the resorptive process. An interim root canal dressing of calcium hydroxide is recommended prior to canal restoration. Once effective canal disinfection and sealing is achieved, the defect [Martin et al., 2003] is repaired by cementum or bone, according to the type of vital tissue found next to the resorption site (periodontal ligament or bone tissue).

Some authors [Van Acker et al., 2015] recommended the use of CBCT (Cone Beam Computed Tomography) for diagnosis and treatment of very complex clinical cases in paediatric patients as well. Its use in paediatric dentistry is mainly suggested for evaluation of both impacted teeth and root resorptions [Hidalgo-Rivas et al., 2014].

In this case report, the treatment and the follow-up of a replanted central incisor affected by IERR and not endodontically treated is presented.

Case report

A 11-year-old male was referred to our office by his dentist with a buccal fistula above tooth 2.1. The parents reported he had suffered the traumatic avulsion of tooth 2.1 six months prior; the tooth had been replanted and splinted within 20 minutes, but the patient went back to observation only after an abscess that determined a buccal fistula. After a periapical x-ray

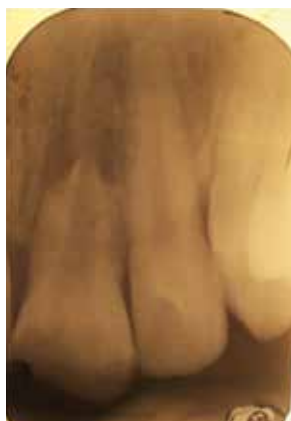

FIG. 1

FIG. 1 Initial periapical x-ray.

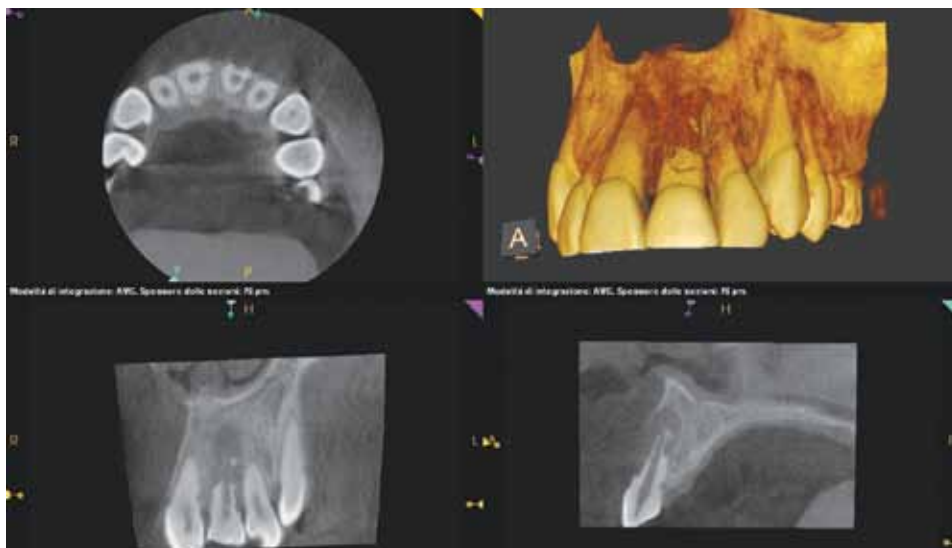

FIG. 2

FIG. 2 Preoperative CBCT.

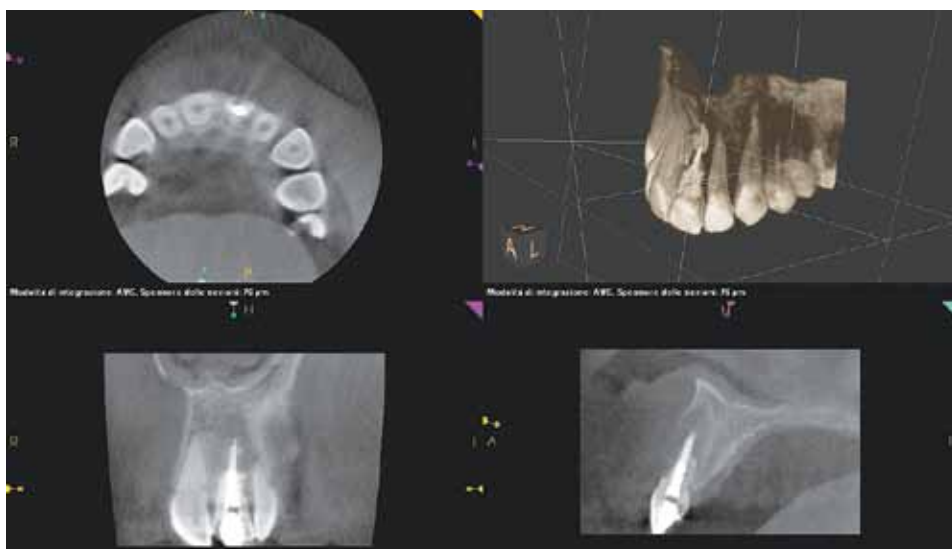

FIG. 3

of the tooth that did not show clearly the extent of the lesion (Fig. 1), the dentist decided to refer the patient to an office provided with a Cone Beam Computed Tomography device for a more accurate radiological examination.

When the patient was visited, the intraoral clinical examination showed a buccal fistula above tooth 2.1, and both teeth 2.1 and 1.1 did not respond to the vitality test. Parental informed consent was obtained, therefore the boy underwent CBCT examination with CS 9000 3D (paediatric setting): x-ray images showed the deep external root resorption of tooth 2.1 and an initial apical root resorption of tooth 1.1 (Fig. 2). The endodontic treatment was planned and performed as follows: tooth 2.1 was isolated with rubber dam and the access cavity was prepared; the working length was determined with apex locator (Root Zx mini, J Morita, Tokyo, Japan) and the root canal system was

irrigated alternating EDTA solution (17%) and 5,25% sodium hypochlorite solution for at least 30 minutes. Subsequently a CaOH paste was placed in the root canal, which was temporarily obturated with Cavit (3M ESPE). A second session was scheduled within 30 days. At the second session, the fistula was no more present. The tooth was then isolated using a rubber dam and other cycles of detersion were performed with 5,25% sodium hypochlorite (NaOCl). The root canal was dried with absorbing paper points placed in the canal at working length. Biodentine (Septodont F) was placed in small increments at the apical third with a dedicated syringe and compacted using large paper points with calibrated lengths progressively smaller to have at least 4-5 mm of seal at the apical third. The material took 15 minutes of setting, then the canal was obturated with canal sealer (Pulp Canal Sealer™ EWT) around the canal walls with a paper point. Injected warm

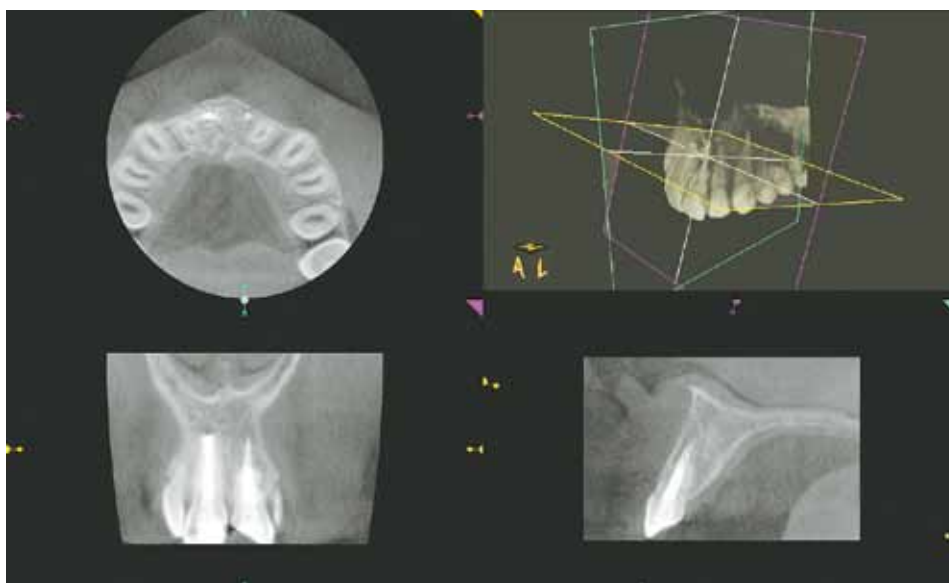


FIG. 4 CBCT at the 1 year follow up.

guttapercha was used to perform the back-packing.

Subsequently, the patient underwent a CBCT exam to check adequacy of the treatment (Fig. 3), and one week later the final restoration was performed with resin composite; afterwards the 1.1 was endodontically treated as well.

The CBCT examination at 12 months (Fig. 4) showed complete healing of the periradicular hard tissues of both treated teeth.

Discussion

Inflammatory external root resorption is a possible complication of traumatic dental injuries [Finucane et al., 2003] when the tooth is luxated or avulsed and replanted. Resorption may, ultimately, result in loss of the tooth.

When pulp necrosis occurs following luxation and avulsion injuries, the necrotic tissue is susceptible to bacterial contamination. The combination of bacteria in the root canal and cemental damage on the external root surface can trigger the onset of IERR [Tronstad, 1988; rope, 2002]. If the resorptive process exposes the dentine, toxins from bacteria present in the tubules and/or the infected root canal can be transmitted to the periodontal ligament. Promoters of hard tissue resorption (including macrophage chemotactic factor, osteoclast activating factor, prostaglandins) are released [Tronstad et al., 1988]. Inflammation in the periodontal ligament and osteoclastic activity may lead to resorption of the lamina dura and of the adjacent bone.

From a radiographic standpoint, external inflammatory resorption is characterised by a progressive loss of tooth substance associated with a persistent or progressive radiolucency in the adjacent alveolar bone [Cvek et al., 1994].

Over the past decade, high-resolution cone beam computed tomography (CBCT) considerably improved radiographic diagnosis [Estrela et al., 2009] in accurately detecting root resorption and chronic apical lesions as well.

According to the Sedentex report the benefits of a CBCT exam must outweigh the potential risks and CBCT should potentially add new information to aid the patient's management at all times. No CBCT should be performed unless a history and clinical examination have been conducted. "Routine" or "screening" imaging is unacceptable [Sedentext, 2012]. Recently, in order to balance the patient protection and technical progress in radiology, the European Society of Endodontology (ESE) introduced the guidelines for using CBCT in diagnosis and management of dental pulp diseases [Patel et al., 2014]. The ESE guidelines permit the use of Focused FOV in "assessment and/or management of root resorption which clinically appears to be potentially amenable to treatment". Furthermore, in the update of AAE and AAOMR Joint Position Statement recently published [2015], Recommendation 12 establish that "Limited CBCT is the imaging modality of choice in the localization and differentiation of external and internal resorptive defects and the determination of appropriate treatment and prognosis".

According to Aps [2013], although the indications for the use of CBCT in paediatric dentistry have not as yet been properly addressed, the three basic principles of radiation protection should be sufficient for the use of CBCT in these patients. Its use must be justified, and benefits must clearly outweigh the potential risks. In any case, the effective radiation dose should not be underestimated, especially in children, who are more susceptible to stochastic biological effects.

There are risks associated with any type of radiation coming from a CBCT device or from a traditional one.

Children under 10 years have a risk factor 3 times higher compared to 30 year-old patients, and patients between 10 and 20 years of age have a risk factor 2 times higher [Whaites et al., 2007]. Because of the higher risk related to young age, every CBCT exam has to be fully justified and performed following special warnings [Theodorakou et al., 2012]. For paediatric use, limited field of view (FOV) devices should be used for most clinical cases, as these allow optimisation of the dose delivered to the patients, facilitating the clinical evaluation of the scanning and reducing the number of incidental findings [Hidalgo Rivas et al., 2015].

Thereafter, the cone beam computed tomography with a limited FOV may be considered for diagnostic assessment and management of some clinical situations, such as IERR. The use of Limited CBCT in diagnosis of root resorption in paediatric patients has been suggested in a paper published by Hidalgo-Rivas et al. [2015].

This young patient arrived to our office with a very low-quality conventional x-ray. It was very hard to obtain information about the extension of both resorption and the periradicular lesion. Because of the requirement of a new and more detailed x-ray exam, we decided to perform a 3D exam using a Limited FOV CBCT device for several reasons.

- 1) CS 9000 3D CBCT device was used, selecting the "child option" for the lower irradiation to the patient. According to Ludlow [2009], this device has a very limited FOV (50x38 mm) and, in the upper frontal area, the adult patient is given an effective dose of only 5.3 microseavert, very closed to a conventional x-ray exposition. Using a specific phantom, Theodorakou et al. [2012] showed that children receive a higher equivalent dose (16-24 microseavert), because of the increased risk factor.
- 2) This device shows high-resolution images (voxel 0,076 mm). In the mentioned paper of Theodorakou et al., CS 9000 3D showed the lowest radiation to patient. The second was Promax 3D (Planmeca Oy, Helsinki, Finland), with an effective dose of 18-24 microseaverts, but using a 0,32 mm Voxel. According to Von Acker et al. [2015], this resolution is too low for its use in endodontics and dento-alveolar traumatology.
- 3) According to the AAE and AAOMR Joint Position Statement [2015], "limited FOV CBCT may provide a dose saving over multiple traditional images in complex cases".

The first exposure was clearly insufficient for a proper assessment of the extension of the resorption and for the formulation of a correct treatment plan; therefore, the analysis of the cost/benefit ratio of a second exposure of the young patient, made us consider that a CBCT conducted with a very low exposure similar to a traditional intraoral x-ray, would provide all the necessary information avoiding additional and

unnecessary intraoral radiographs.

The same considerations made to justify the preoperative x-ray with limited FOV CBCT, guided us in choosing the same exam for the post-operative and 1-year follow-up x-ray. After that, the patient was regularly subjected just to clinical observations.

According to the current guidelines, the recommended treatment for management of IERR is repositioning of the tooth as soon as possible, use of splints, endodontic treatment, and clinical and radiographic control [Diangelis et al., 2012].

Elimination of bacteria from the root canal and/or dentinal tubules by endodontic therapy will arrest the resorptive process. An interim root canal dressing of calcium hydroxide is recommended prior to canal restoration. The mechanism by which calcium hydroxide participates in the reparative process is unclear, but success rates up to 97% have been reported using this method [Cvek et al., 1994; Foreman and Barnes, 1990].

If root canal treatment is delayed beyond 20 days [Hinkfuss et al., 2009], the cemental damage of external root surface allows bacteria in the root canal to determine inflammatory root resorption, and the percentage of success decreases significantly.

In the present case report the treatment of a replanted central incisor with IERR that was not endodontically treated after replantation is described. After a CBCT examination, which allowed a correct evaluation of the position and dimension of the lesion, the treatment consisted of sealing the resorption site with a bioceramic material, treating the tooth endodontically and making the final restoration of the tooth.

Recently MTA have opened up the horizon for root canal sealers; it has been reported to be biocompatible, to stimulate mineralisation and to encourage apatite-like crystalline deposits along the apical and middle thirds of canal walls [Gomes-Filho et al., 2009; Tyagi et al., 2013].

More recently, biodentine and other bioceramic materials have been introduced to the market; biodentine combines the biocompatibility of MTA with more efficient characteristics, such as significantly shorter setting time, good handling characteristics, and no tooth staining. The cement is able to induce hard tissue formation, has antibacterial effect, and forms an effective seal against entrance of microorganisms. Bioceramics has demonstrated similar results to MTA when used for management of internal and external root resorption [Utneja et al., 2015].

The 12-month follow-up clinical examination revealed healthy soft tissues, normal tooth mobility with no signs of ankylosis and normal function of the tooth with minimal discolouration. Radiographic evaluation performed with CBCT showed the arrest of the severe external root resorption, repair of the resorbed tissues in the mid-root level and dentine wall thickening of the apical third of the root; it means that the desired

healing outcome was achieved.

This case report underlines the valuable contribution of CBCT examination for correct diagnosis, and the reliability of bioactive materials to manage cases of severe IERR efficiently.

Conclusions

In the case of IERR, CBCT proved to be more reliable than conventional radiography due to the additional information such as differential diagnosis, true location, shape and size of hard tissues defect. The use of CBCT with limited FOV and low-dose radiation may be particularly suitable in diagnosis, treatment planning and follow-up of these clinical situations in paediatric patients.

Because of its tissue conductive and inductive properties, Biodentine can be considered an effective material for cases of severe inflammatory external root resorption like the one reported in the present study.

References

- › AAE and AAOMR Joint Position Statement – Use of cone beam computed tomography in Endodontics 2015 Update. *Oral Surg Oral Med Oral Pathol Oral Radiol* 2015 Oct;120(4):508-12.
- › Aps JKM. Cone Beam Computed tomography in paediatric dentistry: overview of recent literature. *Eur Arch Paediatr Dent* 2013; 14: 131-40.
- › Bastos JV, Cortes MIS, Silva JFC, Goulart EMA, Colosimo. Gomez EARS, Dutra WO. A study of the interleukin-1 gene cluster polymorphisms and inflammatory external root resorption in replanted permanent teeth. *Int Endod J* 2015; 48(9):878-87.
- › Casaroto AR, Hidalgo MM, Sell AM, Franco SL, Cuman RK, Moreschi E et al. Study of the effectiveness of propolis extract as a storage medium for avulsed teeth. *Dent Traumatol* 2010;26:323–31.
- › Cvek M In: Andreasen JO, Andreasen FM, Andersson L, editors. Textbook and colour atlas of traumatic injuries to the teeth. 3rd edn. Copenhagen: Munksgaard; 1994. p. 556-78.
- › Diangelis AJ, Andreasen JO, Ebeleseder KA, Kenny DJ, Trope M, Sigurdsson A, et al. International Association of Dental Traumatology guidelines for the management of traumatic dental injuries: 1. Fractures and luxations of permanent teeth. *Dent Traumatol* 2012; 28:2-12.
- › Estrela C, Bueno MR, De Alencar AHG, Mattar R, Valladares Neto J, Azevedo BC, De Araújo Estrela CR. Method to evaluate inflammatory root resorption by using cone beam tomography. *J Endod* 2009; 35(11):1491–1497.
- › Finucane D, Kinirons MJ. External inflammatory and replacement resorption of luxated, and avulsed replanted permanent incisors: a review and case presentation. *Dent Traumat* 2003; 19: 170–174.
- › Foreman PC, Barnes IE. A review of calcium hydroxide. *Int Endod J* 1990;23:283-297.
- › Gomes-Filho JE, Watanabe S, Bernabé PF, de Moraes Costa MT. A mineral trioxide aggregate sealer stimulated mineralization. *J Endod* 2009;35:256-260.
- › Hidalgo Rivas JA et Al. The use of cone beam CT in children and young people in three United Kingdom dental hospital. *Int J Pediatr Dent* 2014 Sept; 24(5): 336-48.
- › Hidalgo Rivas JA, Horner K, Thiruvengatchari B, Davies J, Theodorakou C. Development of a low-dose protocol for cone beam CT examinations of the anterior maxilla in children. *Br J Radiol* 2015; 88(1054):20150559.
- › Hinkfuss SE, Messer LB. An evidence-based assessment of the clinical guidelines for replanted avulsed teeth. Part I: timing of pulp extirpation. *Dent Traumat* 2009; 25: 32–42.
- › Ludlow JB. Dosimetry of the kodak 9000 3D small FOV CBCT and panoramic unit. *OJOO* 2009; 107(4): abstract e29.
- › Patel S, Durack C, Abella F, Roig M, Shemesh H, Lambrechts P, Lemberg K. European Society of Endodontology position statement: the use of CBCT in endodontics. *Int Endod J* 2014; 47(6):502–504.
- › Sedentext (2012) Radiation protection no 172: cone beam CT for dental and maxillofacial radiology. Evidence based guidelines. European commission.
- › Theodorakou C et Al. Estimation of pediatric organ and effective doses from dental cone beam CT using anthropomorphic phantoms. *Br J Radiol* 2012; 85:153–160.
- › Tronstad L. Root resorption etiology, terminology and clinical manifestations. *Endod Dent Traumatol* 1988; 4:241-52.
- › Trope M. Clinical management of the avulsed tooth: present strategies and future directions. *Dental Traumatol* 2002;18:1-11.
- › Tyagi S, Mishra P, Tyagi P. Evolution of root canal sealers: an insight story. *Eur J Gen Dent* 2013;2:199- 218.
- › Utneja S, Nawal RR, Talwar S, Verma M. Current perspectives of bio-ceramic technology in endodontics: calcium enriched mixture cement - review of its composition, properties and applications; *Restor Dent Endo* 2015;40(1):1-13.
- › Van Acker JV, Martens LC, Aps JK. Cone-beam computed tomography in pediatric dentistry, a retrospective observational study. *Clin Oral Investig* 2015 Sep 16. [Epub ahead of print]
- › Whaites E, editor. Essentials of dental radiography and radiology. 4th ed. London: Churchill Livingstone Elsevier; 2007b. p. 29–33.